

УДК 636.12.12/12

**ANATOMO-TOPOGRAPHIC FEATURES OF LYMPH NODES IN THE DROMEDARY  
(CAMELUS DROMEDARIUS)****PAVLO GAVRYLIN**, *Sc.D. in veterinary sciences,  
Professor***DJALLAL EDDINE RAHMOUN**, *post graduation in morphology, oncology and animal pathology***LIESHCHOVA MARYNA**, *Ph. D., senior research worker**Dnepropetrovsk State Agro-Economic University,  
Dnepropetrovsk*[deddine44@hotmail.com](mailto:deddine44@hotmail.com)[lieshchova07@gmail.com](mailto:lieshchova07@gmail.com)

*The architecture of the lymph node dromedary (Camelus dromedarius) differs from that shown in the conventional patterns of other mammalian animals, generally formed of a plurality of aggregates, the latter are surrounded by a connective tissue which extends over the whole area surface lymph node and each cluster is a node itself. Vascular distribution in these lymphoid aggregates is relatively abundant and each node receives one or two afferent lymphatic's and is drained by four or five efferent lymphatics. In approximately half of nodes examined, there was extra nodal communications between the lymphatic vessels (afferent and efferent), allowing to bypass the lymph node. Lymph nodes are characterized by their dromedary lobule appearance and size. This lobulated appearance is acquired with age. Indeed in a camel one day we noticed that although the lymph nodes are large, but rather the lobulation is not clear. All forms are possible was lymph nodes ovoid, flattened, elongated, notched, triangular or rounded in some cases*

***Lymph nodes, aggregates, dromedary, lobule***

**Introduction.** Dromedary lymph nodes are studied but often wrongly attributed in scientific journals. We used several different lymph nodes. Aspects of lymph nodes of the dromedary are discussed. The position of the lymph nodes camel is summarized and illustrated in anatomical charts explaining the position and precise topography of each unit. Studies have been conducted to investigate gross aspects, histological of lymph nodes in dromedaries [11], as was the lack of information on the precise anatomy and topography of the lymph nodes on this animal, we made a very advanced to know with certainty what the lymph node is composed of the dromedary and what is its anatomical structure study. According to the authors, it was found that the morphology and structure [2, 13], lymph node dromedary has intermediate characters that take both the mammalian general that the special case of the pig. This animal is usually kept for meat and it is strongly believed that the detailed anatomical data should be made regarding lymph nodes that they play an important

part of the defense mechanism of the body against the invasion of body foreigners [8]. In addition, these lymph nodes, this can be easily palpated in animals during the inspection of the meat. Studies have been conducted to investigate gross, histological aspects of lymph nodes in dromedaries, as was the lack of information about the anatomy and topography of the lymph nodes on this particular animal [3, 4, 5], we had a very advanced knowledge with certainty that the lymph node is composed of the camel and what is the study of the anatomical structure. According to the authors, it was found that the morphology and structure [6, 9], lymph nodes dromedary intermediate characters who are both large mammal that the particular case of pigs.

**The purpose.** Our research will allow us to elucidate the anatomical and topographical structure of the somatic and visceral lymph nodes of the dromedary (*Camelus dromedarius*)

**Material and method.** 50 dromedaries were assigned to this study slaughterhouse Ouargla, in

southern Algeria, in fact after slaughter; the location of the desired node was traversed by using a very accurate diagram of the anatomy of the namely animal anatomical topography accurate lymph nodes. The recognition of the location of the 10 lymph nodes, we have collected and studied at the abattoir and laboratory; 5 somatic: (the Parotid, submandibular, superficial cervical, axillary, popliteal) and 5 visceral: (medial retropharyngeal, caudal mediastinal, portal, jejunum). The measurement of the length and width of each lymph node is made after preparation of lymph node using a scalpel Pack of 5 HS No. 10A and the results are listed on Table and lymph nodes were identified by visual inspection of each image. The identification process is purely visual are: analysis of the size, shape, color, location and proximity of the surrounding structures has proven to be useful for the identification of particular lymph node [7]. Observations obtained were compared with ganglion to better reach a consensus of opinion that has been validated in general in relation to the anatomy atlas. The main characteristics of the majority of lymph

nodes detected identified on the images.

When the identification process is completed, each lymph node is defined by a contour with a marker and the distribution of the lymph nodes requires a detailed topography of the other organs of the dromedary [1], which corresponds to a relation between the descriptions of the lymph nodes relative to adjacent organs. The greatest difficulty, however, is the construction of a model of the architecture of the whole lymph node good preparation of lymph node quote us have the details of all of the unit that may have this shema.

**Results and discussion.** The observations were compared to best reach a consensus of opinion that has been validated in general with reference to the atlas of anatomy. The main characteristics of the majority of lymph nodes detected, identified on the images, are as given in [Table 1]. Most lymph nodes are detected in accordance with the above characterization [12, 15], either round, randomly shaped, and lymph nodes with sharp limits were also found, as shown in.

In the dromedary, we noticed that the lymph node is surrounded by a fibrous capsule, consisting

Table 1. General characteristic of the dromedary lymph nodes

Lymph nodes		Length of L.N cm	Width of L.N cm	Number of kongregate	Form	Color
Somatic lymph nodes	Parotid	3	1	8	flattened, elongated	gray
	Submandibular	9	4	15	ovoid	light brown
	Superficial cervical	9	2	11	ovoid	dark or light brown
	Axillary	5	4	5	ovoid, flattened	gray
	Popliteal	7	4	4	elongated	light brown
Visceral lymph nodes	Medial retropharyngeal	7	6	4	flattened, triangular	Pink or light brown.
	Caudal mediastinal	35	21	13	elongated, triangular	light brown.
	Portal	6	2	4	ovoid	pink
	Jejunum	3	2	5	triangular	light brown
	Medial iliac	7	6	3	elongated, notched	light brown

of collagen fiber, reticular fibers and some elastic fibers. Truss extends the fibrous capsule in the lobules and delimits the parenchyma of the node; these fibrous septae increasingly thin towards the center of the body and the support are the blood vessels and nerves [14]. The color is very variable. Pink, gray, black or pale brown. In the dromedary, the average is 131 lymph nodes divided into 34 groups of 25 and 9 inconstant constant. On palpation confirmed that the occurrence of lymph node is dented rough to the touch, this consistency is due to its rich fibrous tissue [16]. The fibrous tissue is very abundant not only in the capsule and the number of partitions. This fibrous zone is traversed by numerous blood and lymphatic vessels, an overview has given a clear picture of several regular nodes (mammalian deviation) and juxtaposed together in the same housing [10]. The cortex is observable under the capsule with the follicles and germinal centers; but is also observed in the middle of the node, in contact partitions. Each unit shows the usual one node with its cortex and medulla available.

Among somatic lymph nodes examined; we have the parotid lymph node; is constant and unique. There is flattened on one side to the other and measure an average of 3 cm in length by 1 cm wide [Fig. 1]. We have also observed the Submandibular lymph node is located in the caudal angle of the mandible laterally to the region of the throat, cervico-facial under the platysma muscle. It is related to the ventral extremity of the

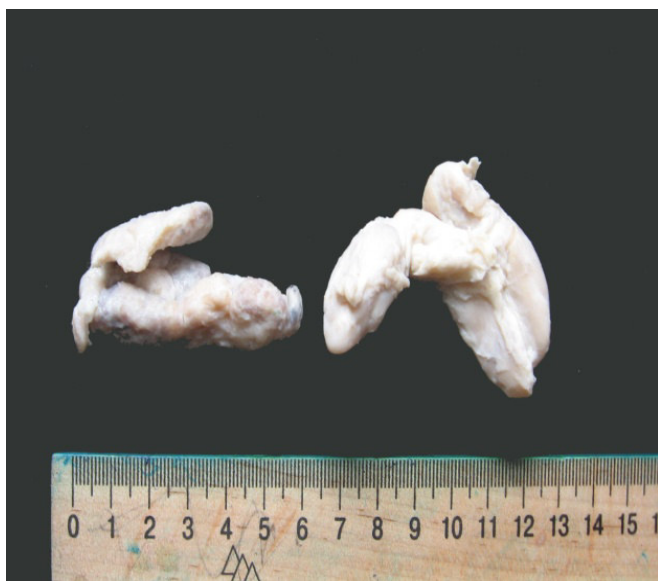

Fig. 1. Parotid lymph node

parotid gland and responds to the ventral board of the facial vein. It is the surface, on its rear board and omohyoideus muscle, in connection with the sublingual vein; it is between 9 cm in length and 4 cm width [Fig. 2].

The cervical lymph node superficial is unique and constant. It is a large oval lymph node and elongated measurement an average of 9 cm long and 2 cm wide. It is located along the cranial edge of the biceps muscle in the space formed by the biceps muscles and omotransversarius neck. It is covered by the brachiocephalic muscle [Fig. 3].

As also we found that the axillary lymph node is always constant, more or less flat almost circular shape. Its dimensions range from 4.5 cm of length to width of 4 cm. He stands up to the 30th ribs on the chest and serratus muscle below the axillary vein. Its deep surface is related to the large round muscle and the thoracodorsal artery [Fig. 4].

The popliteal lymph node is unique and constant. It has an ovoid shape. It is located in the popliteal fossa, the gastrocnemius muscles of the leg to the point of greatest convexity of the muscle belly. [Fig. 5]. The popliteal lymph node is, however, almost hidden by the thick elastic blade strengthens the tibialis fascia surface. This blade extends from the ischial tuberosity to the calcaneus. The node responds to the dorsal edge of the gastrocnemius muscle and caudal edges of the semitendinosus and biceps femoris, it measures

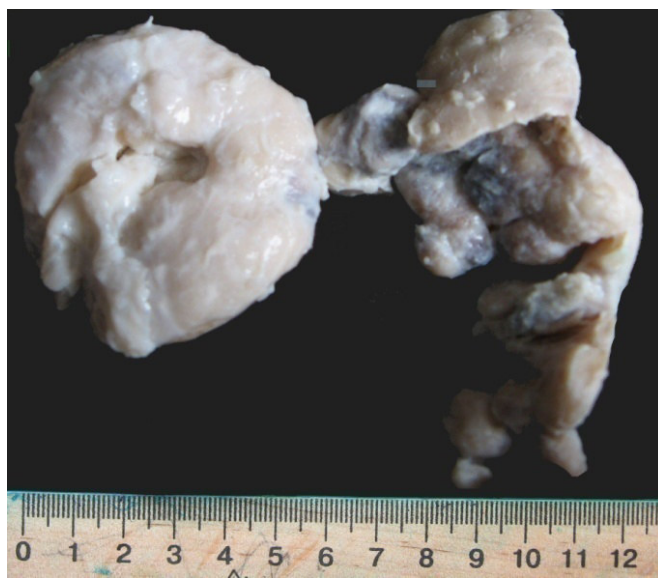


Fig. 2. Sub mandibullary, cervical superficial-lymph node

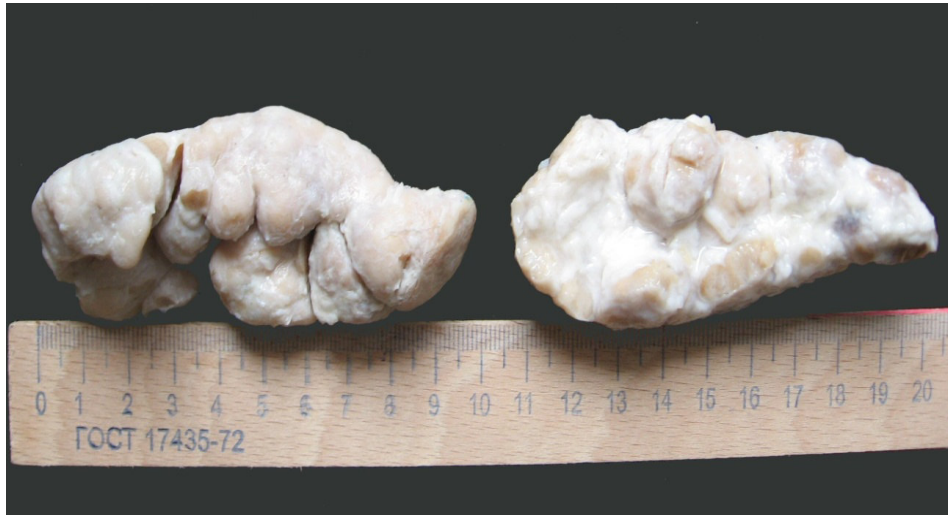

Fig. 3. **Cervical superficial lymph node**

the length of 7 cm to 4 cm in width [Fig. 6].

For visceral lymph nodes studied were selected the retro pharyngeal lymph node is a bulky lymph node dug by a gutter which houses the common carotid artery. It is based on the common carotid artery. It is related to the surface with the mandibular gland and dorsally with occipital artery, it is between 7 cm in length and width of 6 cm. Caudal mediastinal lymph node is always constant and united. This is an enlarged lymph node measuring 35 cm in length 21cm wide. It has the shape of a curvilinear triangle. It is located far back in the caudal mediastinum after passing through the esophagus into the hiatus. It is placed latero-dorsally on the esophagus, along the ventral edge of the abdominal aorta and based

in part on the central portion fleshy pillars of the diaphragm. This extends the ganglion 10 th thoracic vertebrae of the vertebral body to the level of the first lumbar vertebra.

The hepatic portal lymph nodes are elongated and the number 4. They are constant and their size varies from 6 cm length 2 cm wide. Own liver lymph nodes are located in the attachment of the lesser omentum in the portal fissure and against the portal vein. They are partly hidden by the pancreas. So the further jejunal lymph node is smaller, located along the spiral colon. They throw themselves into the para-aortic lymph nodes. It measure 3 cm in length and 2 cm wide.

The medial iliac lymph nodes are not large. They are irregularly shaped. They form an inden-

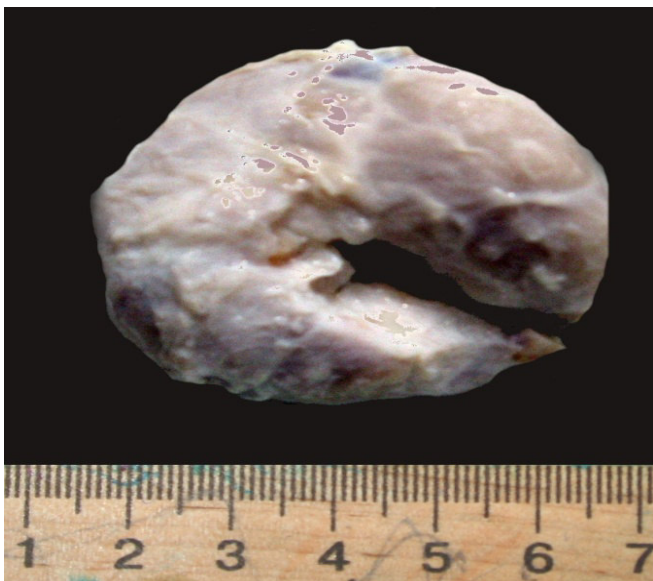


Fig. 4. **Axillary lymph node**

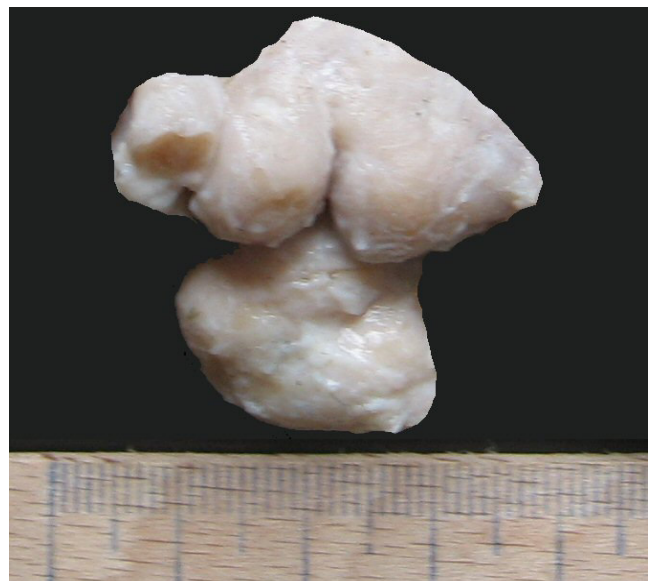

Fig. 5. **Popliteal lymph node**

tation where the external iliac artery passes. It was noted that it is located in the angle formed by the external iliac artery and the internal iliac artery. Most of these nodes are based on the small psoas muscle. It measure 6 cm in length and 4 cm in width [Photo10].

**Conclusions.** The architecture of the lymph node of the dromedary (*Camelus dromedarius*) is formed of a plurality of aggregates, the latter are surrounded by a connective tissue which covers the entire surface of the lymph node is a cluster

and each node lymphatic itself. For after our research can have that lymph node dromedary with its structure is similar to all mammals and specially the pigs.

**Thanks.** The authors wish to thank the abattoir to Ouargla, in southern Algeria for the support and assistance, also the scientific research center of bio-safety and environmental control of agro-industrial complex Dnepropetrovsk state agrarian university for the assistance.

## BIBLIOGRAPHY

1. Sayo A. Viandes de dromadaire (*Camelus tlrometidrius*) et de zebu (*Bos indicus*) / A. Sayo. — ANNEE, 1988. - № 16 — 56 p.
2. The parotid, mandibular and lateral retropharyngeal lymph nodes of the camel (*Camelus dromedarius*) / Abdel-Magied E.M., Taha A.A.M., Al-Qara-wi A.A. // Anat. Histol. Embryol.— 2012, - №30.— P. 199-203.
3. Barone R. Anatomie comparée des mammifères domestiques /R. Barone// Angiologie Tome 5 (2ème édition): VIGOT— 2012.— P. 152—236.
4. Barone R. Anatomie comparée des mammifères domestiques / R. Barone // Tome III: splanchnologie / Tome 1: appareil digestif, appareil respiratoire.— Lyon, ENV, Laboratoire d'anatomie, 1976— 879 p.
5. Cauvet (Cdt) (1925): Le chameau. Tome I anatomie, physiologie, race, extérieur, vie et mœurs, élevage, alimentation, maladies, rôle économique. 784 pp. J. B. Baillière et fils ed. Paris.
6. Heath, T. J. Afferent pathways of lymph flow within the popliteal node in sheep / T. J. Heath, R. L. Kerlin, H. J. Spalding //Journal of Anatomy.— 149.—1986.—P. 65-75.
7. Heath T. J. Pathways of lymph flow to and from the medulla of lymph nodes in sheep / T. J. Heath, H. J. Spalding //Journal of Anatomy.— 155.—1987.—P. 177-188.
8. Saunders C. Mémoires anatomie vétérinaire - Thorax et abdomen Chien - Chat - Cheval - Vache / C Saunders // ELSEVIER/ MASSON.—03/2013.— 15p.
9. Dellman H. D. Textbook of veterinary histology / H. D. Dellman, and E. M. Brown // Lea and Febigar, - Philadelphia, 1976.
10. On the morphology of the liver in the two-humped camel (*Camelius bactrianus*) /H. Endo, C. Gui-Fang, B. Dugarsuren, B. Erdemtu, D. Manglai, Y. Hayashi // Anat. Histol. Embryol.— № 29.— 2000.—P. 243-246.
11. Gahlot T.K. Anatomy and Histology of Camels Ed / T.K. Gahlot, A.S. Saber, S.K.. Nagpal and Jianlin Wang, 1992.
12. L Junqueira, J Carneiro, Long, J. : Basic Histology. A text book Librairie du Liban 5th ed. Nopajaroosri, C.; Luch, S. C. and Simon, (1986)
13. Osman D.I. Morphological observations on the supramammary lymph node of the dromedary camel / D.I. Osman //J. Vet. Sci. Anim. Husbandry, 1988— 27—P. 38-53.
14. Popesco P. Atlas d'Anatomie topographique des mammifères domestiques /Popesco P.— Vanders Ed. Paris, 1962.
15. Saley M., Topographie ganglionnaire et inspection des carcasses de dromadaire (*Camelus dromedarius*) au Niger. Thèse de Doct. Vet. n°15, EISMV /Saley M.; Da-kar, Senegal, 1986.

## АНАТОМО-ТОПОГРАФИЧЕСКИЕ ОСОБЕННОСТИ ЛИМФАТИЧЕСКИХ УЗЛОВ ОДНОГОРБОГО ВЕРБЛЮДА (CAMELUS DROMEDARIUS)

Гаврилин П.Н., Рахмун Джалал Эдин, Лещева М.А.

*Архитектура лимфоузлов одногорбого верблюда (Camelus dromedarius) имеет значительные отличия от классического строения лимфатических узлов других млекопитающих. Лимфатический узел верблюда состоит из нескольких агрегатов, снаружи окруженных соединительной тканью, которая распространяется вглубь паренхимы разделяя ее на отдельные доли. Каждый лимфоидный агрегат значительно васкуляризирован, он получает один или два афферентные лимфатические сосуды и дренирует четыре или пять эфферентных. Лимфатические узлы могут иметь различную форму: овальную, плоскую, удлинненную, зубчатую, треугольную или в некоторых случаях закругленную. Дольчатость лимфоузлов появляется с возрастом*

**Ключевые слова:** лимфатические узлы, агрегаты, верблюд, дольки

---