



## Seasonal changes in the testicular morphology and interstitial tissue histomorphometry of Sahraoui camel under Algerian extreme arid conditions

Djallel Eddine Gherissi, Farida Afri-Bouzebda & Zoubir Bouzebda

To cite this article: Djallel Eddine Gherissi, Farida Afri-Bouzebda & Zoubir Bouzebda (2017): Seasonal changes in the testicular morphology and interstitial tissue histomorphometry of Sahraoui camel under Algerian extreme arid conditions, Biological Rhythm Research, DOI: [10.1080/09291016.2017.1357331](https://doi.org/10.1080/09291016.2017.1357331)

To link to this article: <http://dx.doi.org/10.1080/09291016.2017.1357331>



Published online: 27 Jul 2017.



Submit your article to this journal [↗](#)



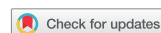Article views: 3



View related articles [↗](#)



View Crossmark data [↗](#)



# Seasonal changes in the testicular morphology and interstitial tissue histomorphometry of Sahraoui camel under Algerian extreme arid conditions

Djallel Eddine Gherissi<sup>a,b</sup>, Farida Afri-Bouzebda<sup>a,b</sup> and Zoubir Bouzebda<sup>a,b</sup>

<sup>a</sup>Department of Veterinary Medicine, Institute of Agronomic and Veterinary Sciences, University of Souk Ahras, Algeria; <sup>b</sup>Laboratory of Biotechnology, Animal Production and Health, University of Souk Ahras, Algeria

## ABSTRACT

The seasonal testicular morphology and the morphometry of the interstitial tissue were studied in 62 camels at Algerian extreme arid region. The maximal testicular size was recorded during the rutting season. In this period, the interstitial tissue occupied high area and volume with significant increase of the intertubular constituent's volume, hypertrophy of the Leydig cell, and maximal number of Leydig cells per testes. Therefore, the highest ratios of seminiferous tubules to interstitial tissue area and volume and the highest fraction of intertubular empty space were recorded during the non-rutting. The greater Leydig cell nucleus size was observed during the post-rutting season. Finally, the numerical density of Leydig cells did not significantly change over the year. These results provide information on the relationship between seasonal changes of camel testicular morphology and the histomorphometry of the testicular endocrine compartment in camels at the arid livestock conditions of the southeastern Algerian desert.

## ARTICLE HISTORY

Received 13 July 2017  
Accepted 17 July 2017

## KEYWORDS

Rutting season; dromedary camel; interstitial tissue; Leydig cells; testicular morphology

## 1. Introduction

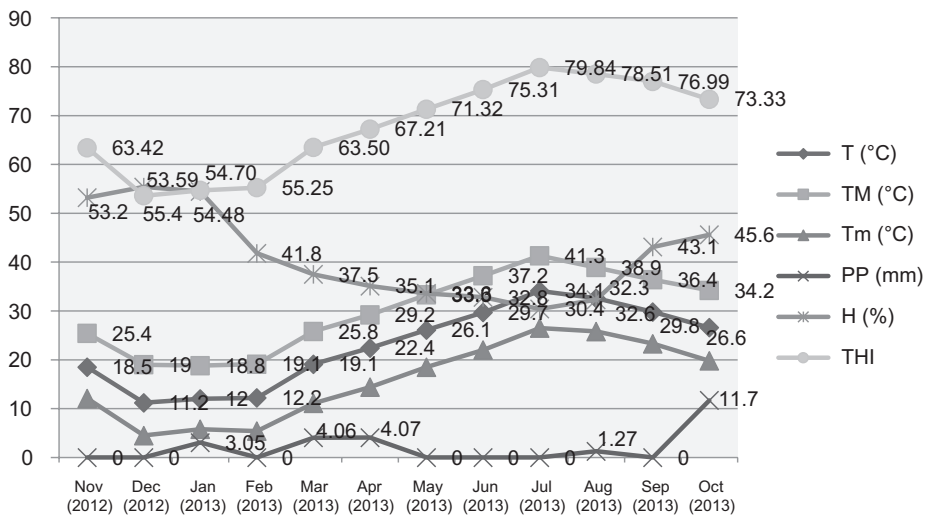
Camels have for over decades played a paramount role in regional development, from Asia, North Africa, and East Africa, respectively. The current evidences show that camels are an important livestock in the livelihood of many of the rural and urban herds' men (Bamwesigye and Pershotam 2016). The camel will not sustain its role as food provider without changing and improving its performance. Efficient reproduction is of utmost importance for intensification and sustainable improvement of animal productivity that requires more use of biotechnologies applied to reproduction. Perfect knowledge of camel seasonal physiological changes characteristics is essential to optimize interventions in both male and female dromedary camel. In this species, testes grow and regress under climatological, geographical, photoperiodic, and food quality interactions (Arthur et al. 1985; Marai et al. 2009; Pasha et al. 2011b, 2013; Gherissi et al. 2014). Therefore, a reliable selection of rutting males based on the testicular morphometry is possible by its strong correlation with sperm volume, the quantity and quality of produced sperm (Akingbemi and Aire 1991; Adeyemo et al. 2007;

Abdullahi et al. 2012; Kastelic 2014). Previous investigations agreed that season has an obvious effect on the testicular tissue and the Leydig cells activity as revealed by their ultrastructure (Abd-Elaziz et al. 2012; Pasha et al. 2013) and by serum concentrations of melatonin, FSH, LH, testosterone, and prolactin in adult camels (Al Qarawi and El Mougy 2008, Waheed et al. 2015). The Elevated steroid hormones concentrations are accompanied by increased sexual behavior, seminal volume, and sperm output (Rahman et al. 2007; El-Kon et al. 2011; Pasha et al. 2015). In mammals, the hypertrophy or hyperplasia of individual Leydig cells had explained seasonally increased Leydig cell volume (Johnson et al. 1986; Neves 1973). Compared to classical seasonal breeders, like hamsters, deer, and brown bear (Gosch and Fischer 1989; White et al. 2005), camel's testis decreased in non-breeding season and they were unable to breed for several months without total cessation of spermatogenesis (Gherissi et al. 2016). Indeed, certain number of active Leydig cells must be continuously required for existing germ cells throughout the year. The objective of the study reported here was to investigate the testicular morphology and describe the histomorphometric changes of the endocrine compartment around the rutting season in Sahraoui camel breed.

## 2. Materials and methods

### 2.1. Description of the study area

The experiment was conducted between November 2012 and October 2013 at El Oued region situated in the extreme arid region of the southeastern of Algeria (Lat: 33°5' and Lon: 6°11'). The monthly meteorological conditions of the study area are showed in Figure 1. The relief of El Oued region is composed of the great eastern erg which is a real sea of sand dunes, the Hamada, that is a tray vast and stony lands, a fairly prospered valleys, and few depressions called the zone of the chotts.



**Figure 1.** Average monthly climatological parameters by Guemmar station (2014).

Notes: T: Average temperature (°C). TM: Maximum temperature (°C). Tm: Minimum temperature (°C). PP: Total rainfall (mm). H: Average relative humidity (%). THI: Temperature-humidity index.

The camel rutting season in the study area is particularly remarkable during the winter season under cold climate. Its precocity, duration, and the peak of sexual activity are strongly influenced by the early rains and thus vegetation cover of pasture.

## **2.2. Experimental animals and samples collection**

The experiment was conducted during three different seasons according to the male camel breeding ability; the rutting season (R) from November to February, post-rutting (PR) season from March to Jun, and non-rutting (NR) season from July to October. Sixty two one-humped male Sahraoui camels aged 4–13 years were utilized in the present work. Of these, twenty studied in the rutting season (R), eighteen studied in the post-rutting season (PR), and 24 studied in the non-rutting season (NR). These animals came from semi-extensive transhumant herds and destined to meat production. They were kept in free stall housing system with fenced yards separately from other animals, and had no contact with female camels. Each animal was fed about 3–5 kg barley grain and 10–15 kg straw with daily watering. Their weigh ranged from 457 to 590 kg. The camels were free from external and internal parasites and without physical defects especially at the testicular region. After slaughter paired testes were collected and dissected from the surrounding tissues then fixed in 10% formaldehyde for histological processing.

## **2.3. Testicular dimensions**

Before the slaughter, for each animal, length (TL), widths (TW), thickness (TT) of right and left testis were measured using sliding calipers. The scrotal circumference (SC) was performed by metric tape as previously described by Gherissi et al. (2014). For the paired testicular volume (PTV), the equation for ellipsoid shape was applied:  $4/3 \pi TL \times TW \times TT$  (REF). Finally, the paired testes weight (PTW) was estimated by the mean of digital scale (Gherissi et al. 2016).

## **2.4. Tissue processing and quantitative testicular histology**

After fixation, proximal, mid, and distal portions of the testes samples were dehydrated through graded percentages of ethanol (65, 75, and 95%), then cleared in xylene and infiltrated and embedded in paraffin wax (Automate circulation system LEICA TP1020 and inclusion station LIECA EG1160). Two serial sections (5  $\mu$ m) were made from each sample (LEICA RM 2235), mounted on to gelatin-coated glass slides and dried overnight at 37 °C and stained with hematoxylin and eosin (H & E). The histological sections were examined using binocular microscope Optika B-600B equipped with a digital camera HIROCAM (5MP) and fitted with a micrometer eyepiece at  $\times 10$ ,  $\times 40$  and  $\times 100$  magnification. Two processing software were used for quantitative histomorphometric study: Axovision Rel 4.6 (Carl Zeiss, Thornwood, NY) and Image J 1.45S (NIH, USA) taking into account the analysis of volume (3D), surface (2D), length (size 1), and number (0 dimensions) of different interstitial tissue structures. The stereological techniques and the histomorphometric methods used in this study were reported in Table 1.

**Table 1.** Histomorphometric characteristics to study the testicular endocrine compartment activity in different rutting seasons on the dromedary camels.

IT (%)	Semi-Sedimented Sigmantation (Khaksar et al. 2013)	The testicular tissue occupied by the Intertubular area	30 cross sections of 5T per testes (5 µm), objective (×40)
ESpc (%)	Semi-Sedimented Sigmantation (Khaksar et al. 2013)	The empty space fraction in the interstitial tissue	30 cross sections of 5T per testes (5 µm), objective (×40)
VIT (cm <sup>3</sup> )	Grid overlapped picture and manual counting method. (Ramaswamy 2005; (Gherissi et al. 2016)	Total volume occupied by IT per testes (cm <sup>3</sup> ) = (IT points/total points) × testicular volume	An average of 600 points per animal Counted
$V_{BVT}$ (µm × 10 <sup>12</sup> , %)	Grid overlapped picture and manual counting method. (Ramaswamy 2005; (Gherissi et al. 2016)	Total volume per paired testes of blood vessels, Leydig cells and conjunctive tissue and their respective % in the interstitial tissue.	An average of 1386 ± 252 points, Testicular sections (5 µm), objective (×100)
$V_{LCr}$ (µm × 10 <sup>12</sup> , %)	Calibrated ocular micrometer (Gherissi et al. 2016)	Average Leydig cell surface = Longitudinal (Leydig Cell Length: LCL) × transversal (Leydig Cell Width: LCW) diameters.	100 Leydig cells per testes (5 µm), objective (×100)
$S_{LC}$ (µm <sup>2</sup> )	Calibrated ocular micrometer (Gherissi et al. 2016)	Leydig cell nucleus diameter	100 nucleus of Leydig cells per testis (5 µm), objective (×100)
$D_{Nu}$ (µm)	Calibrated ocular micrometer (Gherissi et al. 2016)	Leydig cell nucleus volume = (4/3)πD <sub>Nu</sub> <sup>3</sup>	100 nucleus of Leydig cells per testis (5 µm), objective (×100)
$V_{LCNu}$ (µm <sup>3</sup> )	The formula for the volume of a sphere (Pasha et al. 2011b)	Average individual Leydig cell volume = (4/3)πLWC <sup>3</sup>	Mean number per animal testes Mean volume density per animal testes
$V_{LC}$ (µm <sup>3</sup> )	The formula for the volume of a sphere (Pasha et al. 2011b)	Number of Leydig cells per testis = $V_{LCr}/N_{LC}$	
$N_{LCr}$ (×10 <sup>9</sup> )	Verhagen et al. (2014)	Numerical density of Leydig cells = $N_{LCr}/\text{Testicular weight (gr)}$	
$NV_{LC}$ (×10 <sup>7</sup> )	Volume density method (Pasha et al. 2011b)	Calculated ratio	10 testicular sections (5 µm) per animal, objective (×10)
ST/IT	Semi-Sedimented Sigmantation (Khaksar et al. 2013)	Calculated ratio	10 testicular sections (5 µm) per animal, objective (×10)
VST/UIT	Point grid counting (Ramaswamy 2005)	Calculated ratio	10 testicular sections (5 µm) per animal, objective (×10)

## 2.5. Statistical analysis

Analysis of variance was carried out to investigate the rutting season effect, if any, on the studied parameters using GLM procedure by Statistica V.7.0.61.0 (StatSof Inc. 2004). The differences between means clustering were computed for various parameters using Duncan's Multiple Range Test. Results were quoted as arithmetic means clustering  $\pm$  standard deviation ( $M \pm SD$ ) and significance was attributed when  $p < 0.05$ ,  $p < 0.01$  and  $p < 0.001$ .

## 3. Results

### 3.1. Seasonal changes of testicular measurements

The average results of the seasonal testicular measurements were summarized in Table 2. The testicular weight and volume were maintained without significant changes between rutting and post-rutting seasons, however, the testicular circumference dropped significantly between these two seasons ( $p < 0.001$ ). The lowest values of these three parameters were recorded during the hot season ( $p < 0.05$ ), which corresponded to the non-rutting season.

### 3.2. Seasonal changes of the Leydig cells characteristics

Table 3 showed the seasonal changes of different Leydig cells parameters. The high size and volume of the Leydig cells were recorded during the rutting season ( $203.07 \pm 79.32 \mu\text{m}^2$ ,  $7.14 \pm 5.37 \mu\text{m}^3 \times 10^3$ , respectively). These two parameters decreased significantly in the post-rutting season and reached lowest values in the non-rutting season ( $127.14 \pm 61.84 \mu\text{m}^2$ ,  $4.10 \pm 4.18 \mu\text{m}^3 \times 10^3$ , respectively).

The Leydig cell nucleus was almost centrally located. Its average diameter during the rutting and post-rutting seasons was  $5.53 \pm 1.02$  and  $5.83 \pm 1.28 \mu\text{m}$ , respectively ( $p < 0.05$ ), that was decreased significantly in non-rutting season ( $5.11 \pm 1.58 \mu\text{m}$ ,  $p < 0.001$ ). However, highest volume of the Leydig cell nucleus was recorded during the post-rutting season ( $948.20 \pm 626.20$ ,  $p < 0.05$ ).

### 3.3. Seasonal changes of the testicular interstitial area and volume

The Table 4 showed the seasonal changes in the testicular interstitial area and volume. During the rutting season, the interstitial tissue area and volume occupied  $64.60 \pm 10.53\%$  and  $102.93 \pm 25.97 \text{ cm}^3$  without significant difference in the post-rutting season ( $53.77 \pm 14.55\%$ ,  $83.71 \pm 52.37 \text{ cm}^3$ ). These two parameters decreased significantly during the non-rutting season ( $46.39 \pm 14.64\%$   $p < 0.05$ ,  $32.19 \pm 28.74 \text{ cm}^3$   $p < 0.001$ ) (Table 3). In this same context;

**Table 2.** Mean  $\pm$  SD of scrotal circumference, paired testicular weight, and paired testicular volume in male dromedary around rutting season.

Parameters	R	PR	NR	R/PR	R/NR	PR/NR	SL
SC (cm)	31.20 $\pm$ 2.08	26.03 $\pm$ 3.06	22.12 $\pm$ 4.03	***	***	*	***
PTW (g)	190.53 $\pm$ 41.96	202.65 $\pm$ 135.37	110.58 $\pm$ 70.92	NS	**	*	*
PTV (cm <sup>3</sup> )	169.63 $\pm$ 63.83	130.52 $\pm$ 73.02	62.39 $\pm$ 40.69	NS	***	*	***

Notes: Differences among seasons groups were significant at 5% (\*) , 1% (\*\*) and 0.1% (\*\*\*) levels. SL: Significant level. R: Rut. PR: Post Rut. NR: Non Rut. NS: no significant. PTV: Paired testicular volume. PTW: Paired testicular weight. SC: Scrotal circumference.

**Table 3.** Mean  $\pm$  SD of Leydig cells characteristics in male dromedary around rutting season.

Parameters	R	PR	NR	R/PR	R/NR	PR/NR	SL
LCL ( $\mu\text{m}$ )	17.56 $\pm$ 3.83	15.79 $\pm$ 2.99	13.54 $\pm$ 3.48	***	***	***	***
LCW ( $\mu\text{m}$ )	11.31 $\pm$ 2.77	10.14 $\pm$ 2.33	8.99 $\pm$ 2.55	**	***	***	***
$S_{LC}$ ( $\mu\text{m}^2$ )	203.07 $\pm$ 79.32	162.48 $\pm$ 57.12	127.14 $\pm$ 61.84	***	***	***	***
$V_{LC}$ ( $\mu\text{m}^3 \times 10^3$ )	7.14 $\pm$ 5.37	5.25 $\pm$ 3.71	4.10 $\pm$ 4.18	**	***	*	*
$S_{LCNU}$ ( $\mu\text{m}$ )	5.53 $\pm$ 1.02	5.83 $\pm$ 1.28	5.11 $\pm$ 1.58	*	*	***	***
$V_{LCNU}$ ( $\mu\text{m}^3$ )	778.51 $\pm$ 413.70	948.20 $\pm$ 626.20	737.87 $\pm$ 413.70	*	*	*	*

Notes: Differences among seasons groups were significant at 5% (\*), 1% (\*\*) and 0.1% (\*\*\*) levels. SL: Significant level. R: Rut. PR: Post Rut. NR: Non Rut. NS: no significant.

$L_{LC}$ : Leydig Cell Length.  $L_{WC}$ : Leydig Cell Width.  $S_{LC}$ : Leydig Cell size.  $S_{LCNU}$ : Size of the Leydig cell nucleus.  $V_{LCNU}$ : Volume of the Leydig cell nucleus.  $V_{LC}$ : Individual Leydig cell volume.

**Table 4.** Mean  $\pm$  SD of the testicular interstitial area and volume in male dromedary around rutting season.

Parameters	R	PR	NR	R/PR	R/NR	PR/NR	SL
IT (%)	64.60 $\pm$ 10.53	53.77 $\pm$ 14.55	46.39 $\pm$ 14.64	NS	*	*	0.09
ESpc (%)	0.24 $\pm$ 0.35	4.08 $\pm$ 1.1	18.21 $\pm$ 9.71	*	***	***	***
VIT ( $\text{cm}^2$ )	102.93 $\pm$ 25.97	83.71 $\pm$ 52.37	32.19 $\pm$ 28.74	NS	***	***	*
ST/IT	0.58 $\pm$ 0.73	0.83 $\pm$ 0.49	1.34 $\pm$ 0.28	*	**	*	*
VST/VIT	0.61 $\pm$ 0.21	1.009 $\pm$ 0.55	1.12 $\pm$ 0.55	*	***	**	**

Notes: Differences among seasons groups were significant at 5% (\*), 1% (\*\*) and 0.1% (\*\*\*) levels. SL: Significant level. R: Rut. PR: Post Rut. NR: Non Rut. NS: no significant.

IT: Interstitial tissue area. ST: Seminiferous tubules area. Espc: Empty space area in the interstitial tissue. ST/IT: Ratio of seminiferous tubules to interstitial tissue area. VST: Seminiferous tubules volume. VIT: Interstitial tissue volume. VST/VIT: Ratio of seminiferous tubules to interstitial tissue volume.

**Table 5.** Mean  $\pm$  SD of the testicular interstitial tissue composition around rutting season.

Parameters	R	PR	NR	R/PR	R/NR	PR/NR	SL
$V_{BV}$ ( $\mu\text{m}^3 \times 10^{12}$ )	23.19 $\pm$ 5.47	10.86 $\pm$ 6.50	4.66 $\pm$ 3.43	***	***	***	***
$V_{TLC}$ ( $\mu\text{m}^3 \times 10^{12}$ )	22.34 $\pm$ 3.21	13.09 $\pm$ 5.84	5.12 $\pm$ 3.10	***	***	***	***
$V_{CT}$ ( $\mu\text{m}^3 \times 10^{12}$ )	60.93 $\pm$ 19.26	54.82 $\pm$ 35.17	24.52 $\pm$ 20.71	NS	***	***	***
$V_{BV/IT}$ (%)	22.00 $\pm$ 4.01	14.65 $\pm$ 3.55	14.50 $\pm$ 2.68	***	***	NS	***
$V_{TLC/IT}$ (%)	28.71 $\pm$ 11.93	18.68 $\pm$ 4.47	17.25 $\pm$ 3.82	***	***	NS	***
$V_{CT/IT}$ (%)	50.88 $\pm$ 13.18	66.66 $\pm$ 6.36	70.49 $\pm$ 5.34	NS	***	**	*

Notes: Differences among seasons groups were significant at 5% (\*), 1% (\*\*) and 0.1% (\*\*\*) levels. SL: Significant level. R: Rut. PR: Post Rut. NR: Non Rut. NS: no significant.

$V_{BV}$ ,  $V_{TLC}$ ,  $V_{CT}$ : Total volume per paired testes of Blood, Leydig cells, and conjunctive tissue.  $V_{BV/IT}$ ,  $V_{TLC/IT}$ ,  $V_{CT/IT}$  (%): Relative volume of blood vessels, Leydig cells, and conjunctive tissue.

the season affected significantly the ratios of seminiferous tubules to interstitial area (ST/IT) and volume (VST/VIT) ( $p < 0.05$  and  $p < 0.01$ , respectively). Low scores of these ratios were recorded during the rutting season that increased significantly in post-rutting and non-rutting periods. Moreover, the area fraction of the empty space in the interstitial tissue was significantly higher during the non-rutting season (18.21%) compared to the rest of the year ( $p < 0.001$ ).

### 3.4. Seasonal changes of the interstitial tissue composition

Table 5 showed the seasonal changes of the relative volume interstitial tissue components. The volumes of the whole blood vessels (BV) and Leydig cells (LC) and conjunctive tissue (CT) were higher in the rutting season then dropped significantly in non-rutting season

**Table 6.** Mean  $\pm$  SD of the total number of Leydig cells and their testicular density.

Parameters	R	PR	NR	R/PR	R/NR	PR/NR	SL
$N_{LC/T} (\times 10^9)$	$4.23 \pm 2.69$	$2.68 \pm 1.03$	$1.38 \pm 1.46$	*	*	*	*
$NV_{LC} (\times 10^7)$	$2.07 \pm 1.22$	$1.47 \pm 4.47$	$1.43 \pm 7.78$	NS	NS	NS	NS

Notes: Differences among seasons groups were significant at 5% (\*), 1% (\*\*), and 0.1% (\*\*\*) levels. SL: Significant level. R: Rut. PR: Post Rut. NR: Non Rut. NS: no significant.  $N_{LC/T}$ : Number of Leydig cells per testis.  $V_{LC}$ : Numerical density of Leydig cells.

( $p < 0.001$ ). The substantial decrease of BV and LC in the interstitial tissue leaves a high relative volume to the CT during the post-rutting season ( $66.66 \pm 6.36\%$ ,  $p < 0.001$ ) and the non-rutting seasons ( $70.49 \pm 5.34$ ,  $p < 0.01$ ).

### 3.5. Seasonal changes of the number and the numerical density of Leydig cells

Table 6 showed the seasonal variations of the number and the numerical density of Leydig cells in the paired testes of studied camels. The highest average number of Leydig cells was noticed during the rutting season ( $4.23 \pm 2.69 \times 10^9$ ) that decreased significantly during the transition to the post-rutting season ( $p < 0.05$ ). The lowest value of Leydig cells per testes was recorded during the non-rutting season ( $1.38 \pm 1.46 \times 10^9$ ,  $p < 0.05$ ). However, the numerical density of Leydig cells did not show significant differences in relation to the breeding seasons of the year ( $p > 0.05$ ).

## 4. Discussion

The current study aims to investigate the seasonal changes in testicular morphology and histomorphometry of the endocrine compartment in Sahraoui dromedary camel. A significant high testicular measurements (SC, PTW, and PTV) were recorded during the rutting season (winter) compared to the non-rutting season (summer). These results were similar to those obtained by Zeidan et al. (2001), Masood (2007), Pasha et al. (2011b), and Maiada et al. (2013) in Egyptian and Pakistani camels. In seasonal breeders, some reports indicated a strong positive relationship of the individual testes size with the sexual behavior, the male capacity for sperm production and the circulating androgen level.

The proportions of the area occupied IT in the testes of the studies animals can explain reasons of low sperm production in camel species compared with other farm animals in which small proportion of the IT is often described (12–18%) (Pawar and Wrobel 1991; Santos et al. 1999; Alfonso et al. 2002; Dorostghoal et al. 2009; Andreussi et al. 2014). The seasonal changes of the quantitative testicular histology showed a significant decrease of the space and volume occupied by IT during the transition from the winter ( $64.60 \pm 10.53\%$  and  $102.93 \pm 25.97 \text{ cm}^3$ , respectively) to the summer ( $46.39 \pm 14.64\%$  and  $32.19 \pm 28.74 \text{ cm}^3$ , respectively). These results were somewhat similar to those obtained by Singh and Bharadwaj (1978), Tingari et al. (1984), and Zayed et al. (1995) in Indian, Saudi, and Egyptian camels, respectively. During the non-breeding season, the interstitial mass decrease let appear large empty spaces in the intertubular tissue (18.21%). A similar finding was reported by Abd-Elaziz et al. (2012) indicating that during summer the fall of the Leydig cells leads to the appearance of empty spaces in the interstitial tissue.



The seasonal affected more VST/IT than ST/IT ( $p < 0.01$  and  $p < 0.05$ , respectively). These two ratios decreased during the rutting season compared to the non-rutting season. Similarly, Pasha et al. (2013) signaled high ratio of the seminiferous tubule area to the interstitial area during the summer ( $1.90 \pm 0.065$ ) and lower during the winter ( $0.88 \pm 0.056$ ).

The volume of different intertubular tissue constituents displayed high significant seasonal changes. The significant high values of  $V_{BV}$ ,  $V_{TLC}$ , and  $V_{CT}$  were recorded during the rutting season compared to the rest of the year. It was shown that the relative volume of these constituents:  $V_{BV/IT}$ ,  $V_{TLC/IT}$ , and  $V_{CT/IT}$  follow same trend. Our findings are close to those found by Zayed et al. (1995) and Pasha et al. (2011b) who showed that the intertubular compartment was richly vascularized by blood vessels (18%) with maximal Leydig cell volume proportion during the winter (44 and 24.67%, respectively), then decreased significantly and reached lowest levels during the autumn (non-breeding season). These testicular histo-morphological conditions of the non-breeding season were confirmed recently by Maiada et al. (2013) during the hot-humid and hot-dry months. These authors showed interstitial tissues less vascularized and the number of the Leydig cells was numerous during the hot-humid period and increased interstitial connective tissue and atrophy in the Leydig cells during the hot-dry period (Maiada et al. 2013). Therefore, Hussain et al. (2010), Pasha et al (2011a) and Derar et al. (2012) using ultrasound scans showed that these anatomical seasonal changes of the intertubular tissue influenced directly the testicular weight and measurements.

Previously, some authors claim that the remarkable increased average size of Leydig cells indicate their high activity (Friedlander et al. 1984; Zayed et al. 1995; Pasha et al. 2011b; Abd-Elaziz et al. 2012). Our scores regarding the Leydig cell number and individual Leydig cell volume seems lower than those recorded in numerous other species (Mendis-Handagama and Ariyaratne 2008). The main factors of this inter-species variability are related to genetic, endocrine, and environmental factors. In this study, the seasonal variation of the Leydig cell volume represented by their significant hypertrophy during the breeding season ( $7.14 \pm 5.37 \times 10^3 \mu\text{m}^3$ ) and atrophy in the post-rutting season ( $5.25 \pm 3.7118 \times 10^3 \mu\text{m}^3$ ,  $p < 0.01$ ) and non-rutting seasons ( $4.10 \pm 4.18 \times 10^3 \mu\text{m}^3$ ,  $p < 0.001$ ). These findings are due to the correlation of the Leydig cell volume with the number and size of vacuoles indicative of extracted lipid in which cholesterol was utilized as a substrate for steroid biosynthesis (Baker et al. 2003).

The highest diameter of the Leydig cell nucleus was recorded during the spring (post-rutting season) ( $5.83 \pm 1.28 \mu\text{m}$ ). The lowest value of this parameter was obtained in the non-rutting season ( $5.11 \pm 1.58 \mu\text{m}$ ). The nuclear diameter of mature adult-type Leydig cells is also greater when compared to immature adult-type cells, a developmental change that is probable indicative of Leydig cell maturation (Kliesch et al. 1991; Chen et al. 2009; Zirkin 2010). Our findings were close to the seasonal pattern as reported by Abd-Elaziz et al. (2012). These authors recorded in Egyptian camel species increased number of the mature Leydig cells, compared to the numbers of pre-Leydig and immature Leydig cells during the winter, so that, the interstitial cells were mainly of mature type during the spring (Abd-Elaziz et al. 2012). The degenerative lesions appeared in summer and this trend in early and mid-autumn (Abd-Elaziz et al. 2012).

The increased histological proliferation of the interstitial tissue during the rutting season was expressed by a significant elevation of the total Leydig cells number ( $p < 0.05$ ) ( $4.23 \pm 2.69 \times 10^9$ ) as compared to post-rutting ( $2.68 \pm 1.03 \times 10^9$ ) and non-rutting season

( $1.38 \pm 1.46 \times 10^9$ ). However, the numerical density of Leydig cells did not show any seasonal variation ( $p > 0.05$ ). These findings are in agreement with those reported by Zayed et al. (1995) and Pasha et al. (2011b) who recorded maximum number of Leydig cells per testis during winter followed by spring and summer while the lowest values noticed during autumn. Different trend reported by Johnson and Thompson (1987) that new Leydig cells are continually recruited to the existing germ cells population in active and reactivating testes without change in the total number of Leydig cells. Thereby, the seasonal changes in Leydig cell number of the studied camels may be accomplished by altering their seasonal rates recruitment and loss in relation to the seminiferous tubules density in germ cells.

## 5. Conclusion

The seasonal variation of testicular morphology and histomorphometry of the endocrine compartment in Sahraoui one humped camel, showed a testicular cycle characterized by significant high scores of paired testicular weight and volume during the rutting season and low values in the non-rutting season. The rise in testicular measurements was associated with an increase in the area and volume of the interstitial tissue and its constituents (blood vessels, Leydig cells, and conjunctive tissue). However, the ratios of seminiferous tubules to interstitial tissue area and volume were lower during the season of the high testicular activity (winter). The maximal individual Leydig cells volume was recorded in the rutting season but the highest Leydig cell nucleus size and volume were obtained in the post-rutting season. Finally the total number of Leydig cells per testis decreased significantly during the transition from the winter to the summer without significant change of the numerical density of these cells.

This study, by quantification of changes in the testicular morphology and histomorphometry, can provide information on the seasonal degeneration of the endocrine compartment as well as its implications on testicular steroidogenesis and fertility of camel bulls under climatic conditions of the Algerian arid region.

## Acknowledgement

The authors would like to express their gratitude to the Pr. Khammar F., Research Director at the Arid Zone Research Unit, University of Science and Technology Houari Boumediene for her enthusiasm and unlimited help. The technical assistance offered by Mme Kassouri S. is greatly appreciated.

## Disclosure statement

No potential conflict of interest was reported by the authors.

## References

- Abd-Elaziz MI, Kassem AM, Zaghloul DM, Der-Balah AE, Bolefa MH. 2012. Ultrastructure of the interstitial tissue in the testis of Egyptian dromedary camel (*Camelus dromedarius*). Pak Vet J. 32:65–69.
- Abdullahi AI, Musa HAH, Jibril A. 2012. Scrotal circumference and testicular morphometric characteristics of the Camel (*Camelus Dromedarius*) in the Semi-Arid Environment of Northern Nigeria. Int J Morphol. 30(4):1369–1372.
- Adeyemo GO, Longe OG, Adejumo DO. 2007. The reproductive performance of broiler cocks fed cottonseed cake-based diets. Int J Poultry Sci. 6(2):140–144.

- Akingbemi BT, Aire TA. 1991. Testicular dimensions in sperm reserves in the camel (*Camelus dromedarius*) in Nigeria. *Bull Anim Health Prod Afr.* 39:121–123.
- Al Qarawi AA, El Mougy SA. 2008. Seasonality and the melatonin signal in relation to age as correlated to the sexual cycle of the one-humped male camel (*Camelus dromedarius*). *Biol Rhythm Res.* 39(2):131–142.
- Alfonso B, Emilio AP, Rafaela FA, Eduardo A, Jose M. 2002. Quantitative modification of the testicular structure in pigs fed with anabolic doses of clenbuterol. *Vet Res.* 33:47–53.
- Andreussi PAT, Costa DS, Faria FJC, Fernandes CAC, Santos MD, Silva JCB. 2014. Testicular histomorphometric evaluation of Zebu bull breeds. *Braz Arch Biol Technol.* 57(6):900–907.
- Arthur GH, A-Rahim AT, Alhindi AS. 1985. Reproduction and genital diseases of the camel. *Br Vet J.* 141:650–659.
- Baker PJ, Johnston H, Abel M, Charlton HM, O’Shaughnessy PJ. 2003. Differentiation of adult-type Leydig cells occurs in gonadotrophin-deficient mice. *Reprod Biol Endocrinol.* 1(4):1–9.
- Bamwesigye D, Pershotam K. 2016. “Solidarity in a competing world – fair use of resources” The role of Camel production in regional development: case of East Africa. Vienna: Austria Tropentag; p. 19–21.
- Chen H, Ge R-S, Zirkin BR. 2009. Leydig cells: from stem cells to aging. *Mol Cell Endocrinol.* 306:9–16.
- Derar RD, Hasan AH, Ahmad A. 2012. Reference values for the genitalia of male dromedary before and after puberty using caliper and ultrasonography in subtropics. *Theriogenology.* 77:459–465.
- Dorostghoal M, Erfani-Majd N, Goorani-Nejad S. 2009. Stereological study of Arabian ram testis during different seasons. *Iran J Vet Res.* 10:360–366.
- El-Kon II, Heleil BA, Mahmoud SA. 2011. Effect of age and season on the testicular sperm reserve and testosterone profile in camel (*Camelus dromedarius*). *Anim Reprod.* 8(3):68–72.
- Friedlander M, Rosenstrauch A, Bedrak E. 1984. Leydig cell differentiation during the reproductive cycle of the seasonal breeder *Camelus dromedarius*: an ultrastructural analysis. *Gen Comp Endocrinol.* 55:1–11.
- Gherissi DE, Afri-Bouzebda F, Bouzebda Z, Lamraoui R. 2014. Morphometric variations and endocrine changes of the one-humped male camel in relation to reproductive activity. *Ruminant Sci.* 3(1):9–18.
- Gherissi DE, Afri-Bouzebda F, Bouzebda Z, Lamraoui R. 2016. Testicular morphology and stereological evaluation of the seminiferous tubules around the rutting season of Sahraoui dromedary camel. *Global Vet.* 17(6):568–576.
- Gosch B, Fischer K. 1989. Seasonal changes of testis volume and sperm quality in adult fallow deer (*Dama dama*) and their relationship to the antler cycle. *Reproduction.* 85:7–17.
- Hussain R. 2010. Morphological and functional characteristics of the testis of one-humped camel (*Camelus dromedarius*) in the natural ecology of Punjab, Pakistan. [Ph. D., thesis]. Faisalabad, Pakistan: University of Agri-culture.
- Johnson L, Thompson DL. 1987. Effect of seasonal changes in Leydig cell number on the volume of smooth endoplasmic reticulum in Leydig cells and intratesticular testosterone content in stallions. *Reproduction.* 81:227–232.
- Johnson L, Donald L, Thompson JR. 1986. Seasonal variation in the total volume of Leydig cells in stallions is explained by variation in cell number rather than cell size. *Biol Reprod.* 35:971–979.
- Kastelic JP. 2014. Understanding and evaluating bovine testes. *Theriogenology.* 81(1):18–23.
- Khaksar Z, Jelodar G, Hematian H, Poorahmadi M. 2013. Ovarian histomorphometry at puberty in rat offspring from diabetic mothers. *World J Zool.* 8(1):24–29.
- Kliesch S, Schweifer B, Niklowitz P, Nieschlag E, Bergmann M. 1991. The influence of LH and/or FSH on Leydig and Sertoli cell morphology after testicular involution in the Djungarian hamster, *Phodopus sungorus*, induced by hypophysectomy or short photoperiods. *Andrologia.* 23(2):99–107.
- Maiada WA, Allam Abdalla EB, Zeidan AEB, Farouk MH, Abd El-Salaam AM. 2013. Morphological and histological changes in the camel testes in relation to semen characteristics during breeding and non-breeding seasons. *J Am Sci.* 9(11s):74–82.
- Marai IFM, Zeidan AEB, Abdel-Samee AM, Abi-Zaid A, Fadiel A. 2009. Camels, reproductive and physiological performance traits as affected by environmental conditions. *Trop Subtrop Agro-ecosys.* 10:129–149.

- Masood A. 2007. Studies on the morphology of male reproductive system of one-humped camel (*Camelus dromedarius*) kept under natural ecology of Pakistan [MSc (Hons.) Thesis] Faisalabad: University of Agriculture.
- Mendis-Handagama SM, Ariyaratne HB. 2008. Effects of hypothyroidism on anti-mullerian hormone expression in the prepubertal rat testis. *Histol Histopathol.* 23:151–156.
- Neaves WB. 1973. Changes in testicular leydig cells and in plasma testosterone levels among seasonally breeding rock hyrax. *Biol Reprod.* 8:451–466.
- Pasha RH, Qureshi AS, Lodhi L, Jamil H. 2011a. Biometric and ultrasonographic evaluation of the testis of one-humped camel (*Camelus dromedarius*). *Pak Vet J.* 31:2074–7764.
- Pasha RH, Qureshi AS, Lodhi LA, Jamil H, Masood A, Hamid S, Iqbal J, Kamran Z, Khamas WA. 2011b. Morphological seasonal changes in the testis of one-humped camel (*Camelus dromedarius*). *J Camel Pract Res.* 18:145–158.
- Pasha RH, Qureshi AS, Rehman ZU, Khamas WA. 2013. Seasonal anatomical changes in the testis of the one-humped camel: a review. *Eur J Anat.* 17(3):132–141.
- Pasha RH, Qureshi AS, Khanum SA. 2015. Seasonal variations in the sex-steroid hormones and behavior of one humped male camel (*Camelus dromedarius*) in Punjab. *Pak Vet.* 3(1):26–32.
- Pawar HS, Wrobel KH. 1991. Quantitative aspects of water buffalo (*Bubalus bubalis*) spermatogenesis. *Arch Histol Cytol.* 54:491–509.
- Rahman Z, Ahmad N, Bukhari SA, Akhtar N, Haq IU. 2007. Serum hormonal, electrolytes and trace element profiles in the rutting and non-rutting one-humped male camel (*Camelus dromedarius*). *Anim. Reprod. Sci.* 101:172–178.
- Ramaswamy S. 2005. Pubertal augmentation in juvenile rhesus monkey testosterone production induced by invariant gonadotropin stimulation is inhibited by estrogen. *J Clin Endocrinol Metab.* 90:5866–5875.
- Santos RL, Silva CM, Ribeiro AFC, Vasconcelos AC, Pesquero JL, Coelho SG, Serakides R, Reis SR. 1999. Effect of growth hormone and induced IGF-I release on germ cell population and apoptosis in the bovine testis. *Theriogenology.* 51:957–984.
- Singh UB, Bharadwaj MB. 1978. Morphological changes in the testis and epididymis of camels (*Camelus dromedarius*). *Acta Anat.* 101:274–279.
- Tingari MD, Ramos AS, Gaili ESE, Rahma BA, Saad AH. 1984. Morphology of the testis of the one-humped camel in relation to reproductive activity. *J Anat.* 139:133–143.
- Verhagen I, Ramaswamy S, Teerds KJ, Keijer J, Plant TM. 2014. Time course and role of luteinizing hormone and follicle-stimulating hormone in the expansion of the Leydig cell population at the time of puberty in the rhesus monkey (*Macaca mulatta*). *Andrology.* 2(6):924–930.
- Waheed MM, Ghoneim IM, Alhaider AK. 2015. Seminal plasma and serum fertility biomarkers in dromedary camels (*Camelus dromedarius*). *Theriogenology.* 83(4):650–654.
- White Don Jr, Berardinelli JG, Aune KE. 2005. Seasonal differences in spermatogenesis, testicular mass and serum testosterone concentrations in the grizzly bear. *Ursus.* 16(2):198–207.
- Zayed AE, Hifny A, Abou-Elmagd A, Wrobel KH. 1995. Seasonal changes in the intertubular tissue of the camel testis (*Camelus dromedarius*). *Ann. Anat.* 177:199–212.
- Zeidan AEB, Habeeb AAM, Ahmadi EAA, Amer HA, Abd El-Razik A. 2001. Testicular and physiological changes of the male dromedary camels in relation to different ages and seasons of the year. Proceedings of 2nd International Conference on Animal Production and Health in Semi-Arid Areas, El-Arish, North Sinai, Egypt.
- Zirkin BR. 2010. Where do adult Leydig cells come from? *Biol Reprod.* 82:1019–1020.